BALKAN JOURNAL OF STOMATOLOGY

BaSS

ISSN 1107 - 1141

Acrylic Spacer in Treatment of TMJ Ankylosis (A Technical Report)

SUMMARY

TMJ ankylosis results from trauma, infection and inadequate surgical treatment of condylar area. Many techniques for treatment of this disorder have been described in the past. But none of them have been achieved a high success rates. Limited range of interincisal opening due to relapse, loss of vertical height of the affected ramus, foreign body reactions and reankylosis are expected complications.

In this paper, an unusual application and shape of acrylic spacer in the treatment of TMJ ankylosis is presented.

Key words: Temporomandibular joint, ankylosis; Spacer, acrylic

Orhan Güven
University of Ankara,
Faculty of Dentistry,
Department of Oral and Maxillofacial Surgery,

TECHNICAL REPORT (TR)
Balk J Stom, 2000; 4:

Introduction

Temporomandibular joint (TMJ) ankylosis is a disabling condition creating difficulties in jaw function. Hypomobility not only affects the TMJ but surrounding structures as well. Factors causing TMJ ankylosis are well known and include trauma, local systemic infection, and inadequate surgical intervention of condylar area.

Numerous techniques have been proposed in treatment of TMJ ankylosis in adults, including gap arthroplasty[1], variety of spacers[2-4], and costochondral grafts[5].

In this paper we present an acrylic spacer which is innovative in shape.



Figure 1. Diagram of the procedure

Technique

Patients were operated under general anesthesia using nasal-endotracheal intubation. Through the preauricular approach the ankylotic area is clearly exposed. A 1-2 cm gap is created, and care should be taken in order not to damage the internal maxillary artery or pterygoid plexus. A spherical acrylic spacer is inserted between the 2 segments, by preparation of 2 concave cavities on both articular surfaces with the use of large round burr (Fig. 1). The acrylic spacer separates the segments and allows free movement, preventing reunion.

After surgery, patients were advised to undergo physiotherapy. Although this was painful during the first week, most patients showed gradual progress during this stage.

Figure 2 reveals a huge bony block of osteoma, where due to excessive bone formation resection was made on the ascending ramus above the third molar (Fig. 3), followed by placement of the spherical acrylic spacer (Fig. 4).

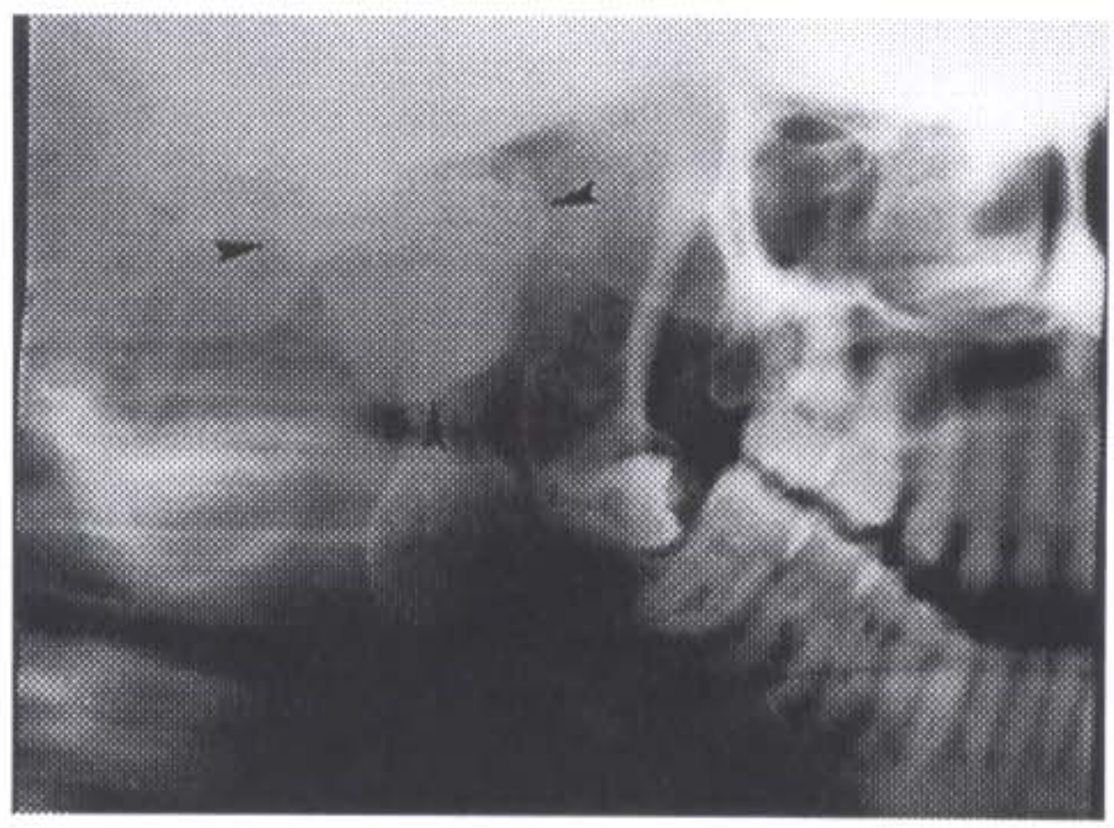

Figure 2. Radiograph of patient demonstrating a hudge bony block in TMJ area

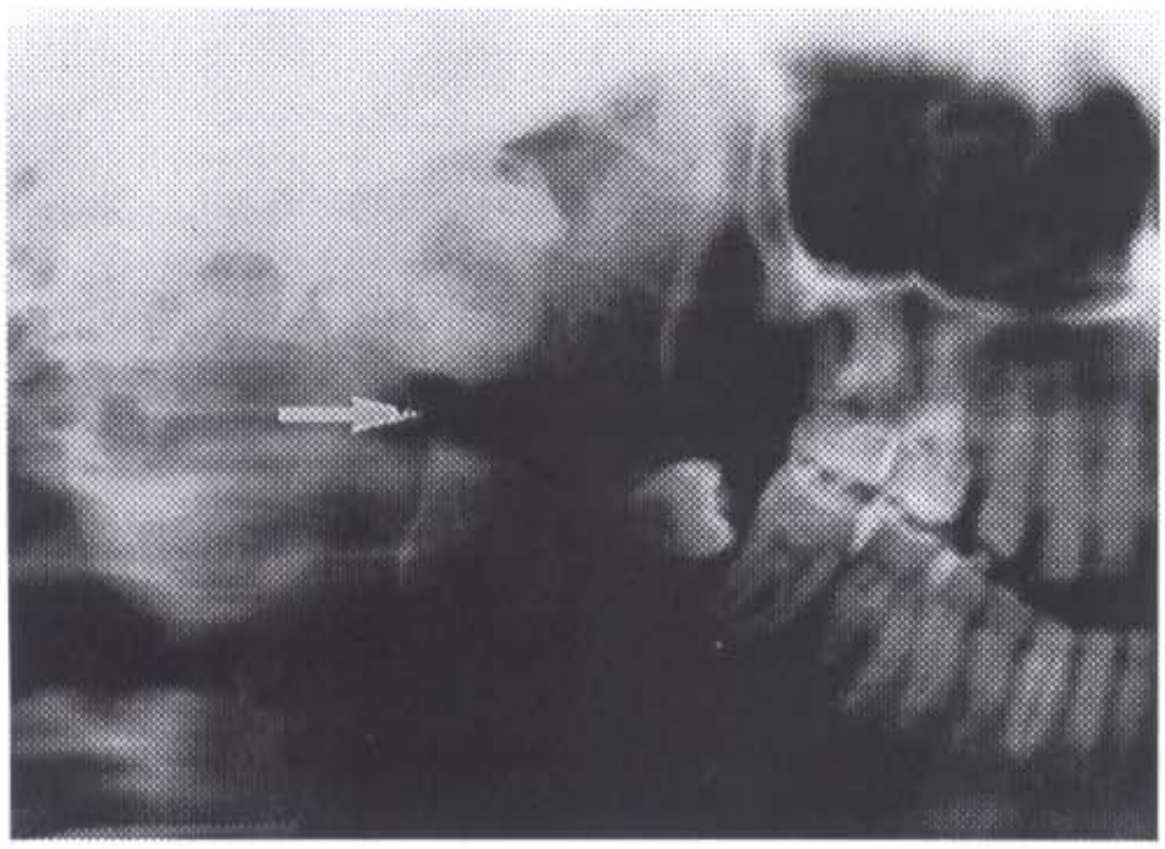

Figure 3. Postoperative panoramic radiograph demontrating the level of resection

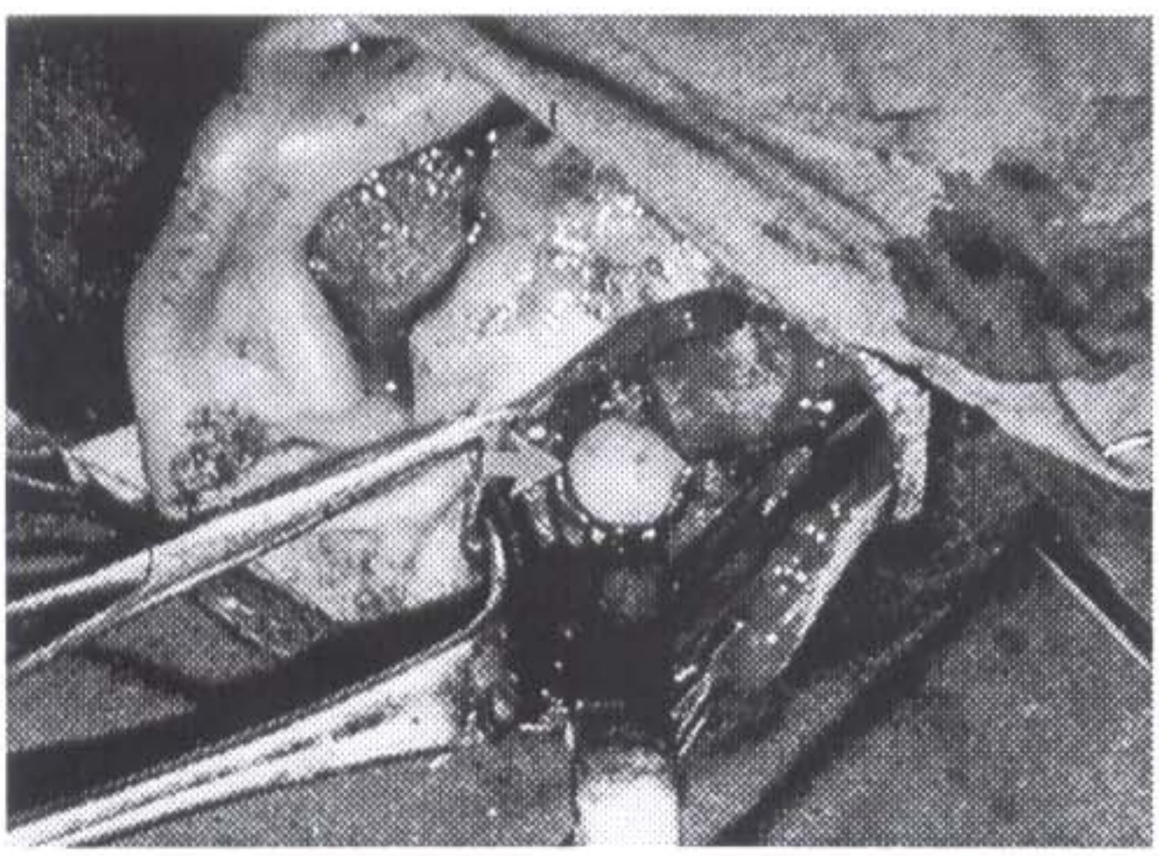

Figure 4. Intraoperative view of reconstruction. Spherical acrylic was placed between the 2 segments

Discussion

Treatment of TMJ ankylosis should be surgery, and many surgical techniques have been suggested. According to the literature, the first attempt to treat this condition by surgery was made by Humprey[6]. Verneuil[7] made the first interposition arthroplasty. During the last decades of the 19th century, Rizoli[8] described horizontal resection of the ramus in TMJ ankylosis. Risdon[9] used gold foil to coat the glenoid fossa to prevent reankylosis. Eggers[10] described the placement of tantalum foil in arthroplasty. Following this, Walker[11] advocated the use of fascia and sylastic in TMJ ankylosis. In the ensuing years, Christensen[2] and Robinson[3] reported some modifications of fossa implants. Borçbakan[12] reported the first series, consisting of 110 cases with surgical treatment of TMJ ankylosis using acrylic condyle. Khein et al[13], Kummoona[4], Sonnenburg and Sonnenburg[14] reported the use of metallic fossa condylar prosthesis. Kent et al[15] reported successful results with the use of proplast coated metallic condylar prosthesis. In the same year, Rajgopal et al[1] reported the cases treated by gap arthroplasty. Borçbakan[12] and Sawhney[16] based their studies on 88 and 70 patients respectively, who were treated with acrylic spacer and reported no foreign body reaction. The use of spherical acrylic spacer was first described by Borçbakan[17]. This type of spacer enabled a patient free rotation of mandible, a considerable improvement on the technique developed by Sawhney[16] which allowed only hinge movement. Advantages of this technique are shorter operating time, and its very low cost.

References

1. *Rajkopal A, Banerji PK, Batura V, Sural A.* Temporomandibular ankylosis. A report of 15 cases. *J Max- Fac Surg*, 1983; 11:37-41.
2. *Christensen RW.* Mandibular joint arthrosis corrected by the insertion of cast vitallum glenoid fossa prosthesis: a new technique. *Oral Surg*, 1958; 17:712-722.
3. *Robinson M.* Temporomandibular ankylosis corrected by creating a false silastic sponge fossa. *J South Calif Dental Assoc*, 1968; 36:14-16.
4. *Kummoona R.* Functional rehabilitation of ankylosed temporomandibular joints. *Oral Surg*, 1978; 46:495-505.
5. *El-Sheikh MM, Medra AM.* Management of unilateral ankylosis associated with facial asymmetry. *J Cranio Maxillofac Surg*, 1997; 25:109-115.
6. *Humprey.* As cited by *Borçbakan C.* 1968; 1856.
7. *Verneuil.* As cited by *Borçbakan C.* 1968; 1860.
8. *Rizoli.* As cited by *Borçbakan C.* 1968; 1860
9. *Risdon FE.* Ankylosis of the temporomandibular joint. *J Am Dent Assoc*, 1934; 21:1933-1936.
10. *Eggers GWN.* Arthroplasty of temporomandibular joint in children with interposition of tantalum foil: a preliminary report. *Bone Joint Surg*, 1946; 28:603-606.
11. *Walker RW.* Arthroplasty of the ankylosed temporomandibular joint. *Am Surg*, 1958; 24:474-485.
12. *Borçbakan C.* L'utilisation du condyle acrylique dans l'ankylose temporomaxillaire. *Rew Stom*, 1968; 69:600-603.
13. *Khein CL, DesPrez JP, Converse CF.* A new procedure for temporomandibular joint replacement. Case Report. *Plast Reconstr Surg*, 1974; 53:221-226.
14. *Sonnenburg I, Sonnenburg M.* Total condylar prosthesis for alloplastic jaw articulation replacement. *J Maxillofac Surg*, 1985; 13:131-135.
15. *Kent JN, Misiek DJ, Akin RK, Hinds EJ, Hams CA.* Temporomandibular joint condylar prosthesis: A ten year report. *J Oral Maaxillofac Surg*, 1983; 41:245-249.
16. *Sawhney CP.* Bony ankylosis of the temporomandbular joint. *Plast Reconstr Surg*, 1986; 77:29-38.
17. *Borçbakan C.* Personal communication. 1985.

Correspondence and requests for offprints to:
Orhan Güven
Yesilyurt Sokak, No: 24/15,
06690 Asagi Ayranci,
Ankara, Turkey

Journal of Cranio-Maxillo-Facial Surgery (1992) **20**, 244–247
© 1992 European Association for Cranio-Maxillo-Facial Surgery

JOURNAL OF CRANIO-MAXILLO-FACIAL SURGERY

Fractures of the maxillofacial region in children

Orhan Güven

Department of Oral and Maxillofacial Surgery (Head: Prof. S. Demiralp, DDS, PhD), Faculty of Dentistry, University of Ankara, Ankara, Turkey.

SUMMARY. **83 children with maxillofacial fractures have been analyzed according to, aetiology, age, sex, type, and site of fractures. The results showed a high male to female ratio. Mandibular fractures were the commonest, in the condylar region in particular. The commonest causes in descending order were falls, bicycle accidents and at play.**

KEY WORDS:
Fractures – Maxillofacial – Children

INTRODUCTION

Maxillofacial fractures in children are less common than in adults. A number of factors, including elasticity of the bone in children, the growth process in the young bone (*McGuirt* and *Salisbury*, 1987), the presence of developing tooth germs and lack of an adequate number of permanent teeth and the small crown form of the deciduous teeth (*Amartunga*, 1988), all influence the pattern of fracture, its management and postoperative period of fixation. 83 cases of maxillofacial fractures in children are analyzed according to aetiology, age, sex, type, and site of fracture and treatment methods in three different centres in Ankara, Turkey, during different periods in the last 12 years.

MATERIAL AND METHODS

The case histories of 83 children with maxillofacial fractures treated in three different centres were analyzed. 24 patients were treated during 1977–1978 by the Department of Otorhinolaryngology of Ankara University, while 29 cases were treated at the Department of Oral and Maxillofacial Surgery of Ankara University, during 1982–1986, and the remaining 30 were patients who received treatment in the Maxillofacial Surgery Department of the State Hospital, Ankara during 1989–1990.

RESULTS

This report evaluates the experience with 83 children with maxillofacial trauma treated in different periods (Fig. 1). 57 of the patients (68.67 %) were male and 26 (31.33 %) were female giving a high male-to-female ratio (Fig. 2). However, this ratio revealed a higher predominance of male patients as compared with male predominance in the third group.

The age distribution is noted in Table 1. The mean age in the first group was 6.79, in the second, 7.72 and in the last group, 7.13 years

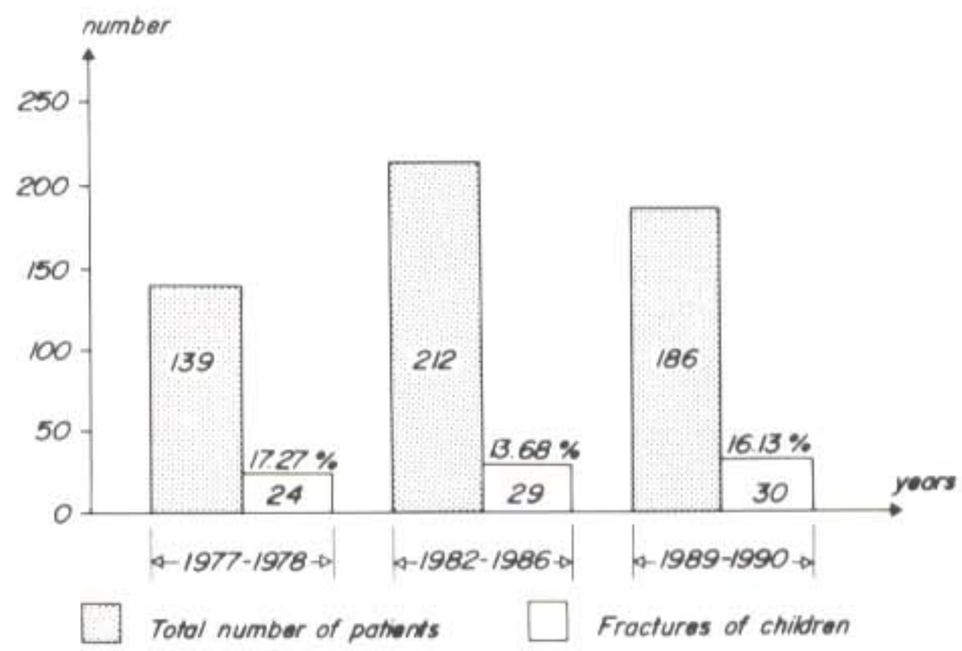

Fig. 1 – Fractures in children out of total number of patients.

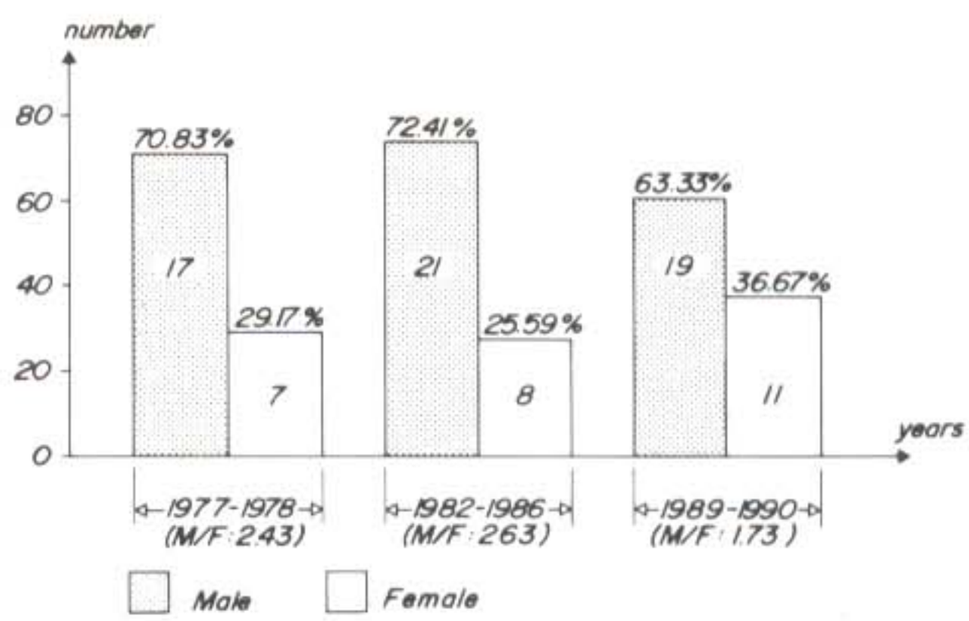

Fig. 2 – Sex distribution (M/F: Male/Female).

Table 1 – Distribution

	N	$\bar{x} \pm S\bar{x}$	Median	Min
1st Group	24	6.79 ± 0.62	6	2
2nd Group	29	7.72 ± 0.58	8	3
3rd Group	30	6.83 ± 0.60	7	1
Total	83	7.13 ± 0.35	7	1

Table 2 – Site of fractures

	1st Gr.	%	2nd Gr.	%	3rd Gr.	%	Total	%
Maxilla	5	20.83	4	13.79	3	10.00	12	14.46
Mandible	19	79.17	25	86.21	27	90.00	71	85.54
Total	24		29		30		83	

Table 3 – Anatomical site of mandibular fractures

	1st Gr.	%	2nd Gr.	%	3rd Gr.	%	Total	%
Condyle	5	26.32	8	32.00	7	25.93	20	28.17
Ramus	1	5.26			1	3.70	2	2.82
Angle	2	10.53	1	4.00			3	4.23
Body	4	21.05	6	24.00	7	25.93	17	23.94
Canine region	3	15.79	7	28.00	7	25.93	17	23.94
Alveolar process	4	21.05	3	12.00	5	18.52	12	16.90
Total	19		25		27		71	

Table 4 – Anatomical site of maxillary fractures

	1st Gr.	2nd Gr.	3rd Gr.	Total
Alveolar	5	3	3	11
Le Fort		1		1
Total	5	4	3	12

Anatomical sites of maxillofacial injuries are depicted in Tables 2, 3 and 4. The most common injuries in the three groups were condyle fractures (28.17 %). Mandibular body fractures tended to reveal increasing numbers in all groups (23.94 %). The fractures in the canine area were also the second commonest (23.94 %). Alveolar fractures were the next common (16.90 %). Fractures of the maxilla were less common than the mandibular ones (14.46 %).

Falls were found to be the most common cause (45.78 %), followed by traffic and bicycle accidents (28.92 %). Play accidents were the third most common aetiological factor (20.48 %). The remainder were due to horse kicks and dog bites (4.82 %) (Table 5).

The majority of the fractures (51.82 %) were treated by hand-made arch bar fixation (Table 6). Wiring the teeth alone was used in 38.55 % of cases. In the alveolar and green-stick fractures, besides teeth wiring we used silk sutures to fix the adjacent tooth in some cases after reducing the fragments by digital pressure (6.02 %). In the maxillary fractures, arch bar fixation and a head bandage were preferred (2.41 %). Only in one case was open reduction and interosseous lower border wiring utilized (1.20 %).

Table 6 – Treatments used

Treatment	Number of patients	%
Arch bar fixation	43	51.81
Wiring teeth only	32	38.55
Digital pressure + fixation by suture material	5	6.02
Arch bar fixation + head bandage	2	2.41
Intraosseous wiring	1	1.20
Total	83	

DISCUSSION AND CONCLUSIONS

The results of our study showed that the frequency of maxillofacial fractures in children in our population is not high. *Gussack* et al. (1987) reported a similar

Table 5 – Aetiology of fractures

	1st Gr.	%	2nd Gr.	%	3rd Gr.	%	Total	%
At home	7	29.17	9	31.03	6	20.00		
Falls							38	45.78
from height	5	20.83	4	13.79	7	23.33		
Traffic and bicycle acc.	6	25.00	8	27.59	10	33.33	24	28.92
Play acc.	4	16.67	7	24.14	6	20.00	17	20.48
Horse kick	2	8.33	1	3.45				
Others							4	4.82
Dog bite					1	3.33		
Total	24						83	

incidence in paediatric patients (14.5%). However, *Bochlogyros* (1985), *Amartunga* (1988), reported fewer fractures in children.

In this study, the peak incidence was in the 6–8 year age-goup. This similarity in incidence was found to be unique when compared with the results of *Hagan* and *Huelke* (1961); *Al-Aboosi* and *Perriman* (1976); *Amartunga* (1988).

The sex distribution of maxillofacial trauma at a national level has shown a high male predominance. The reason is that boys are generally more boisterous than girls and spend more time outdoors as *Al-Aboosi* and *Perriman* (1976) stated.

The aetiology of maxillofacial trauma revealed that falls are the main causative factor in adults in the same population, in whom falls were the third aetiological factor (*Borçbakan* et al., 1978; *Güven*, 1988). Under 3 years of age, the most accidents were falls at home. *Nimityongskul* and *Auderson* (1987) reported the falls in detail and classified them as falls out of bed, crib, couch, chair, wagon, rocking horse, and from a height. Traffic and bicycle accidents were found to be the next most common causes in contrast to the studies of *Khosla* and *Boren* (1971); *Lamberg* (1978); *Bochlogyros* (1985); *Amartunga* (1988).

The most common associated injuries in the three groups were to the lips and tongue, while panfacial soft tissue injuries were not remarkable. This differs from the studies of *Needleman* (1986); *Gussack* et al. (1987).

In contrast to the reports of *Danielsen* (1972); *Laskin* (1973); *Needleman* (1986), injuries of the maxillofacial area due to child abuse were not common in our population. This may be a reflection of local traditions.

In our series, isolated dental trauma was not common, as these patients are usually treated by dentists or department of paedodontics in our country.

In general, mandibular fractures are common facial injuries treated by maxillofacial surgeons and they occur twice as frequently as midfacial fractures. There is also a general trend in other reported series and also our findings show a decreased incidence of midface fractures in the paediatric age group (*Oikarinen* and *Malmstöm*, 1969; *Hall*, 1972; *Reil* and *Kranz*, 1976; *Gussack* et al., 1987). The reason for this may be attributed to the developmental aspects of the facial skeleton. The incidence of midface fractures in children is low but they do occur. The incidence of midface fractures in children exhibits a tendency to an increase in with age.

Condylar fractures were the most common site, as reported by many authors. The results of *Reil* and *Kranz* (1976); *McGuirt* and *Salisbury* (1987); *Amartunga* (1988) confirmed our findings. This differs from the studies of *Oikarinen* and *Malmström* (1969); *Al-Aboosi* and *Perriman* (1976). The high incidence of condyle fractures may be due to the high content of medullary bone with only a thin rim of cortex (*James*, 1985).

Although the reports of *Oikarinen* and *Malmström* (1969); *Al-Aboosi* and *Perriman* (1976) showed the majority of the fractures seen in their studies to be in the mandibular body, our series revealed body fractures were the second most common site.

In the treatment of fractured jaws in children, two principles must be considered; a short period of fixation and early mobilization and training exercises. Due to the high osteogenic potential and rapid healing of the facial skeleton in children, 2–3 weeks is adequate fixation. In children, postoperative feeding presents problems and the conical shape of the deciduous teeth makes wiring difficult.

The treatment of condylar fractures in children needs particular attention. The management has long been a matter of controversy (*Thoma*, 1954; *Archer*, 1966). Open reduction with intraosseous fixation, immobilization with intermaxillary fixation and non-immobilization and early movement are the alternatives in treatment. Although the principles of fracture treatment are reduction and fixation, the majority prefer conservative fixation, *Ivy* loop wires, or simple wires placed round the teeth, or head bandages to fix the fragments or teeth temporarily. Only a few cases have been treated surgically. We believe that conservative treatment will avoid external scars, injury to the inferior alveolar nerve and developing permanent tooth follicles. If these methods give less than satisfactory occlusion, orthodontic treatment at a late stage may correct minor discrepancies. The three different series did not show the expected differences in aetiology, sex, type of fractures or treatment although they cover more than 10 years.

Acknowledgement

I would like to express my sincere thanks to A. Perriman, BDS, FDS, RCS, Scunthorpe, UK, for his invaluable advice and help in the preparation of this manuscript.

References

Al-Aboosi, K., A. Perriman: One hundred cases of mandibular fractures in children in Iraq. Int. J. Oral Surg. 5 (1976) 8

Amartunga, N. A. De S.: Mandibular fractures in children. A study of clinical aspects, treatment needs, and complications. J. Oral Maxillofac. Surg. 46 (1988) 637

Archer, W. H.: Oral Surgery. 4th ed., Saunders, Philadelphia, 1966, p. 836

Bochlogyros, P. N.: A retrospective study of 1521 mandibular fractures. J. Oral Maxillofac. Surg. 43 (1985) 597

Borçbakan, C., M. Gerçeker, O. Güven: Çene kırıkları üzerine bir klinik araştırma. T. Otorienolareng. Bül. 3 (1978) 257

Danielsen, K.: Scandinavian Society of Forensic Odontology. Newsletter. 3 (1972) 93

Gussack, G. S., A. Luterman, R. W. Powell, K. Rodgers, M. L. Ramenofsky: Pediatric maxillofacial trauma: Unique features in diagnosis and treatment. Laryngoscope 97 (1987) 925

Güven, O.: A comparative study on maxillofacial fractures in Central and Eastern Anatolia. J. Cranio-Max.-Fac. Surg. 16 (1988) 126

Hagan, E. H., D. F. Huelke: An analysis of 319 case reports of mandibular fractures. J. Oral Surg. 19 (1961) 93

Hall, R. K.: Injuries of the face and jaws in children. Int. J. Oral. Surg. 1 (1972) 65

James, D.: Maxillofacial injuries in children. In: Rowe and Williams (eds.): Maxillofacial trauma. Churchill Livingstone, Edinburgh 1985, p. 538

Khosla, V. M., W. Boren: Mandibular fractures in children and their management. J. Oral Surg. 29 (1971) 116

Lamberg, M. A.: Maxillofacial fractures – an epidemiological and clinical study on hospitalised patients. Proc. Finn. Dent. Soc. 74 (1978) 113

Laskin, D. M.: The battered-child syndrome. J. Oral Surg. 31 (1973) 903

McGuirt, W. F., P. L. Salisbury: Mandibular fractures. Arch. Otolaryngol. Head Neck Surg. 113 (1987) 257

Needleman, H. L.: Maxillofacial trauma in child abuse: Types, prevalence, management, and the dental profession's involvement. Pediatr. Dent. 8 (1986) 71

Nimityongskul, P., L. D. Anderson: The likelihood of injuries when children fall out of bed. J. Pediatr. Orthop. 7 (1987) 184

Oikarinen, V. J., M. Malmström: Jaw fractures. Suom. Hammaslaak. Toim. 65 (1969) 95

Reil, B., S. Kranz: Traumatology of the maxillofacial region in childhood. (Statistical evaluation of 210 cases in the last 13 years.) J. Max.-Fac. Surg. 4 (1976) 197

Thoma, K. H.: Treatment of condylar fractures. J. Oral Surg. 12 (1954) 112

Orhan Güven, DDS, PhD
Tunalı Hilmi Caddesi
No 26/2-06660 Küçükesat
Ankara
Turkey

Paper submitted 9 November 1991
Accepted 3 February 1992

Int. J. Oral Maxillofac. Surg. 1987; **16**: 445–447

(Key words: *traumatology; zygoma, arch fracture; surgery, oral and maxillofacial*)

Stabilisation of the delayed zygomatic arch fracture

ORHAN GÜVEN

Department of Oral and Maxillofacial Surgery, Faculty of Dentistry, University of Ankara, Beşevler, Ankara, Turkey

ABSTRACT – Most fractures of the zygomatic arch do not require active fixation after reduction. After the replacement of the fragments in the week following injury, fragments are held in correct position. Although fragments can be reduced after the first week, stabilisation cannot be provided properly. After several months, replacement of the fracture will be almost impossible. This report presents a technique by using an extra-oral acrylic appliance in the delayed zygomatic arch fracture.

(Accepted for publication 5 September 1986)

Many methods have been described for repositioning zygomatic arch fractures in the literature[3, 5–7]. Usually in earlier cases, the reduction fragments remain in a stable position. If the reduction has been delayed and the alignment of the fragments cannot be achieved or maintained, surgical methods at one or all fracture sites, particularly at the zygomatic arch, are necessary.

Several extraoral fixation methods have been proposed to fix the unstable fractures. Extraoral fixation can be performed by placing a wire around the zygomatic arch and attaching the wire to a plaster headcap by using a stainless steel synthetic bow that extends ear to ear[4] or by using a Fox eye shield[2]. A Frac Sur (Roger Andersen) Unit is inserted through the skin into the depressed zygoma[1]. Holding the described appliances in these methods can be unbearable for the patient. Recently, VAN DER WAAL & DEVISSCHER[8] have used a modified airway in fixation of the unstable zygomatic arch fracture. In this article, a technique of using an extraoral acrylic appliance in delayed zygomatic arch fracture is presented.

Technique

An impression is taken from the healthy part of the face to provide symmetrical reduction of the zygomatic arch. A plaster model is prepared and a self-curing acrylic bow is constructed on the model. The thickness of the acrylic bow is about 2 mm. To prevent undesirable movements, some retention sites are trimmed on the upper and lower edges of the bow (Figs. 1, 2). To avoid the skin irritation, the edges of the bow are polished and smoothed.

Fragments are repositioned with an elevator. The wires are passed around the zygomatic arch by a Kelsey-Fry instrument, then the wires are

Fig. 1. Fragments held in position by using the acrylic bow.

Fig. 3. Radiograph shows reduction and fixation of fracture.

placed on the retention sites and twisted around the acrylic bow (Figs. 1, 3). An iodoform vaseline gauze is placed between the skin and the acrylic bow to prevent skin necrosis. 3 weeks later, the acrylic bow is removed.



Fig. 2. A self-curing acrylic bow to fix the unstable fragments.

This technique is less obstructive and more comfortable for the patient. In employing this appliance, the operative procedure can be simplified and the complications decreased. Moreover, to take an impression from the healthy side of the face and prepare the appliance, similar in form to the healthy zygoma, will enable us to achieve symmetric and better anatomic repositioning.

References

1. Archer, W. H.: Oral and maxillofacial surgery, 5th edition. W. B. Saunders, Philadelphia 1975, p. 1274.
2. Blevins, C. & Gross, B. D.: A method of fixation of the unstable zygomatic arch fracture. *J. Oral Surg.* 1979: **37**: 602.
3. Brown, J. B., Fryer, M. P. & McDowel, F.: Internal wire-pin fixation for fractures of the upper jaw orbit, zygoma and severe facial crushes. *Plast. Reconstr. Surg.* 1952: **9**: 276.

4. GEHRE, G.: Zur retention chirurgish reponierter jochbein- und jochbogenfracturen. Dtsch. Zahaertzl. Z. 1961: **22**: 1451.
5. GILLIES, H. D., KILNER, T. P. & STONE, D.: Fractures of malar-zygomatic compound, with a description of a new X-ray position. *Br. J. Surg.* 1927: **14**: 651.
6. LORE, J. M.: *An atlas of head and neck surgery*, 2nd edition. W. B. Saunders, Philadelphia 1973, p. 422.
7. POZATEK, Z. W., KABAN, L. R. & GURALNICK, W. C.: Fractures of the zygomatic complex: an evaluation of surgical management with special emphasis on the eyebrow approach. *J. Oral Surg.* 1971: **31**: 141.
8. VAN DER WAL, K. G. H., DEVISSCHER, J. G. A. M.: Fixation of the unstable zygomatic arch fracture. *J. Oral Surg.* 1981: **39**: 783.

Address:

Orhan Güven
Yesilyurt Sokak
No: 24/15
Aşağı Ayrancı
Ankara
Turkey