

A clinical study on temporomandibular joint ankylosis[☆]

Orhan Güven *

University of Ankara, School of Dentistry, Department of Oral and Maxillofacial Surgery, 06500 Beşevler, Ankara, Turkey

Received 18 January 1999; received in revised form 7 May 1999; accepted 14 May 1999

Abstract

Objective: Temporomandibular joint (TMJ) ankylosis results from trauma, infection and inadequate surgical treatment of the condylary area. Many techniques for treatment have been described so far. However, none of them gave uniformly successful results. A limited range of intrinsic opening due to relapse, loss of vertical height of the affected ramus, foreign body reactions and reankylosis are expected complications. However, wide bone resection, the use of interpositional spacer, insensitive and aggressive physiotherapy immediately after the operation are the basic principles as agreed by many authors. In this article, a review of the historical background of the treatment has been discussed.

Methods: A clinical and retrospective evaluation of 42 patients treated for this disorder showed that 89% of all patients had unilaterally and 11% had bilateral ankylosis. From the viewpoint of the techniques we used, patients fell into three groups. In two groups, two different type of spacers were used, and in the third group gap arthroplasty were performed for the treatment of TMJ ankylosis.

Results: Our results revealed a predominance of traumatic aetiology. The highest incidence was between the ages of 11 and 20. A total of 45.24% of the patients were treated by interpositional arthroplasty by using acrylic spacer, 11.90% of the patients by sylvastic sheet used as an interpositional material and the rest of the cases (42.86%) were treated only by gap arthroplasty.

Conclusion: The advantages of the spherical acrylic spacer and gap arthroplasty were discussed. The advantages of the techniques are, shorter operating time, and more importantly its very low cost. © 2000 Elsevier Science Ireland Ltd. All rights reserved.

Keywords: TMJ; Ankylosis; Condyl; Spacer; Arthroplasty; Child

1. Introduction

Temporomandibular joint (TMJ) ankylosis is a disabling condition of mastication. Hypomobility affects the surrounding structures as well as TMJ. As early as 1938 it is classified into two types by Kazanjian [1]; intra-articular and extra-articular ankylosis. Present classification includes bony, fibrous, fibroosseous, complete and incomplete [2,3].

The causes of the TMJ ankylosis are the well known trauma and local-systemic infection. Trauma, which is the most important etiologic factor in causing TMJ often resulting in haematoma, which eventually organizes and ossifies. In some of the cases, excessive bone formation

causes the bony thickening in front of the tragus. The thickness of the bony block varies with the severity of the injury [1,4]. Infection in this area is due to otitis media or mastoiditis, and hematogenous infections. The other etiologic factors are rheumatoid arthritis, Paget's disease, ankylosing spondylitis, pseudohypoparathyroidism, psoriasis and burns.

Intrinsic opening (IO) shows the severity of the ankylosis. Less than 5 mm of IO reveals a complete ankylosis. In unilateral cases mandible can be forced to open because of the elasticity of the mandible and the minimal mobility of the cranial sutures.

Facial asymmetry is the classic feature in unilateral cases. The chin deviates toward the affected side. Vertical height of the affected side is shorter when compared with the unaffected side. A complete absence of mouth opening and recession of the chin are typical characteristics of the bilateral ankylosis. The degree of recession and the asymmetry of the mandible depend on the growth situation and the onset of ankylosis.

[☆] This paper is dedicated to Professor Cihat Borçbakan, M.D. who studied the largest population of TMJ ankylosis in our country until his death in 1991.

* Present address: Yeşilyurt Sokak, No: 24/15, 06690 Aşağı Ayrancı, Ankara, Turkey. Tel.: +90-312-4278072; fax: +90-312-2210938/4676832.

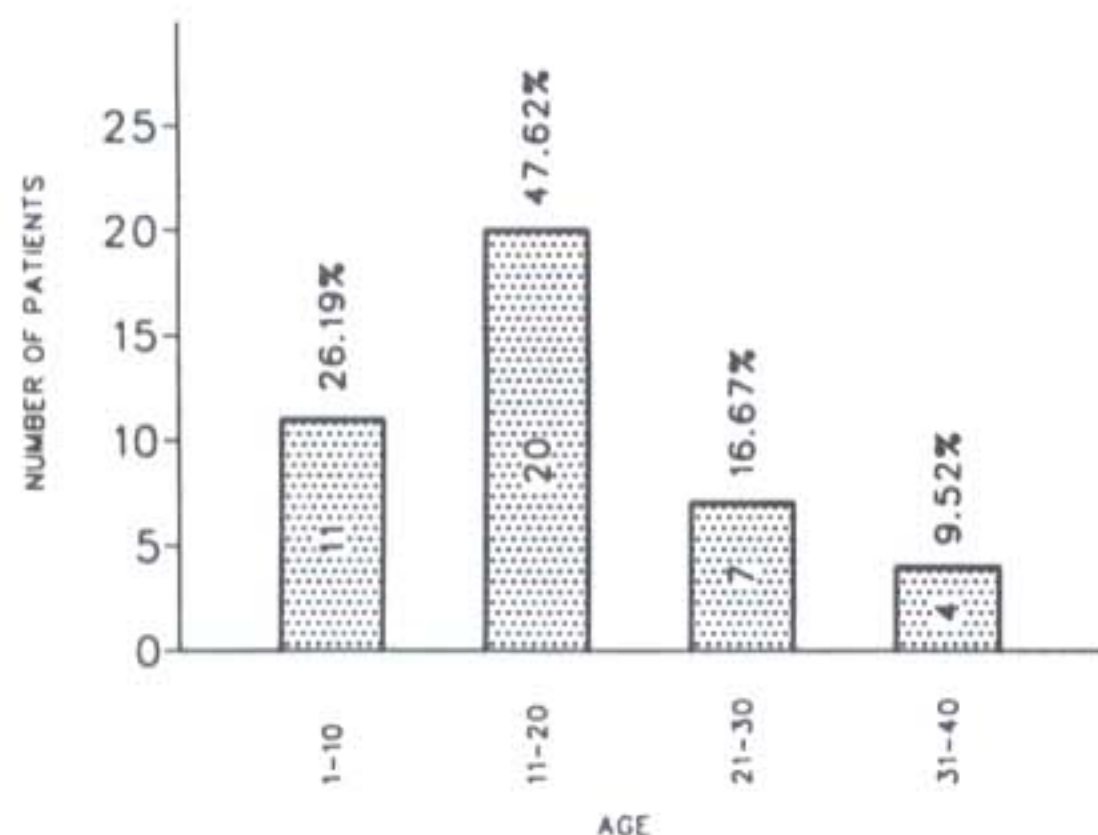


Fig. 1. Distribution according to the age.

M. digastricus and M. mylohyoideus produce marked notching in the lower border of the mandible in front of the insertion of the M. massetericus and M. pterygoideus medialis [3].

Orthodontic anomalies and unhealthy hygienic conditions can often be observed in both unilateral and bilateral cases.

TMJ reconstruction and arthroplasty attempts for freeing of ankylosed mandible are not new. According to Verneuil [5] the first arthroplasty was made by Percy and Barton in 1826. In 1860 Verneuil [5] was the first to suggest the interposition muscle and fascia between the bony cuts, and then many of the materials proposed for TMJ arthroplasty: autogenous bone [6,7] and cartilage [8,9], muscle [10], fat [11], dermis [10], fascia [12], skin [13], metatarsal [6], and sternoclavicular joint [14]. Numerous alloplastic materials have been used for partial or total reconstruction of the TMJ [15–26].

The vast number of techniques tried over the years illustrates the difficulty that has been experienced in producing a satisfactory method for the reconstruction of TMJ. The literature contains a multitude of isolated cases and small series reports. Most give an account of techniques with subjective descriptions of success or

failure and the most of the authors claim that their technique prevent reankylosis, but Norman's [27] experience in reankylosis is not rare.

The time of the diagnosis, the type of operation and the policy of treatment vary from one country to another. However, the main principles are the same: (a) satisfactory resection of the ankylosed segment; (b) use of interpositional spacer, if it is needed; (c) early aggressive and insistent postoperative physiotherapy [28–31].

In this paper, the historical development of the treatment of TMJ ankylosis and the surgical techniques developed at our institution were summarized.

2. Patients and methods

A clinical and retrospective evaluation of 42 patients (23 female, 19 male) treated for this disorder, showed that 89% of all patients had unilateral and only 11% had bilateral ankylosis. The highest incidence were observed in the 11–20 age group (47%) followed by the 1–10 age group (26%) (Fig. 1).

Falling accidents during early childhood was the common etiologic factor (40%) in our study and seven patients had been injured in traffic accidents. Infection was seen in only two cases (Fig. 2). Although five patients were unable to provide the relevant details about the source of their disorder it is reasonable to speculate that they were caused by the misuse of forceps during birth or falling accidents. Four older patients in the group attributed their disorder to inadequate treatment of maxillofacial injury following an accident.

3. Surgical techniques

All the patients were operated under general anesthesia using nasal intubation technique. In order to approach the TMJ area, a preauricular incision was made.

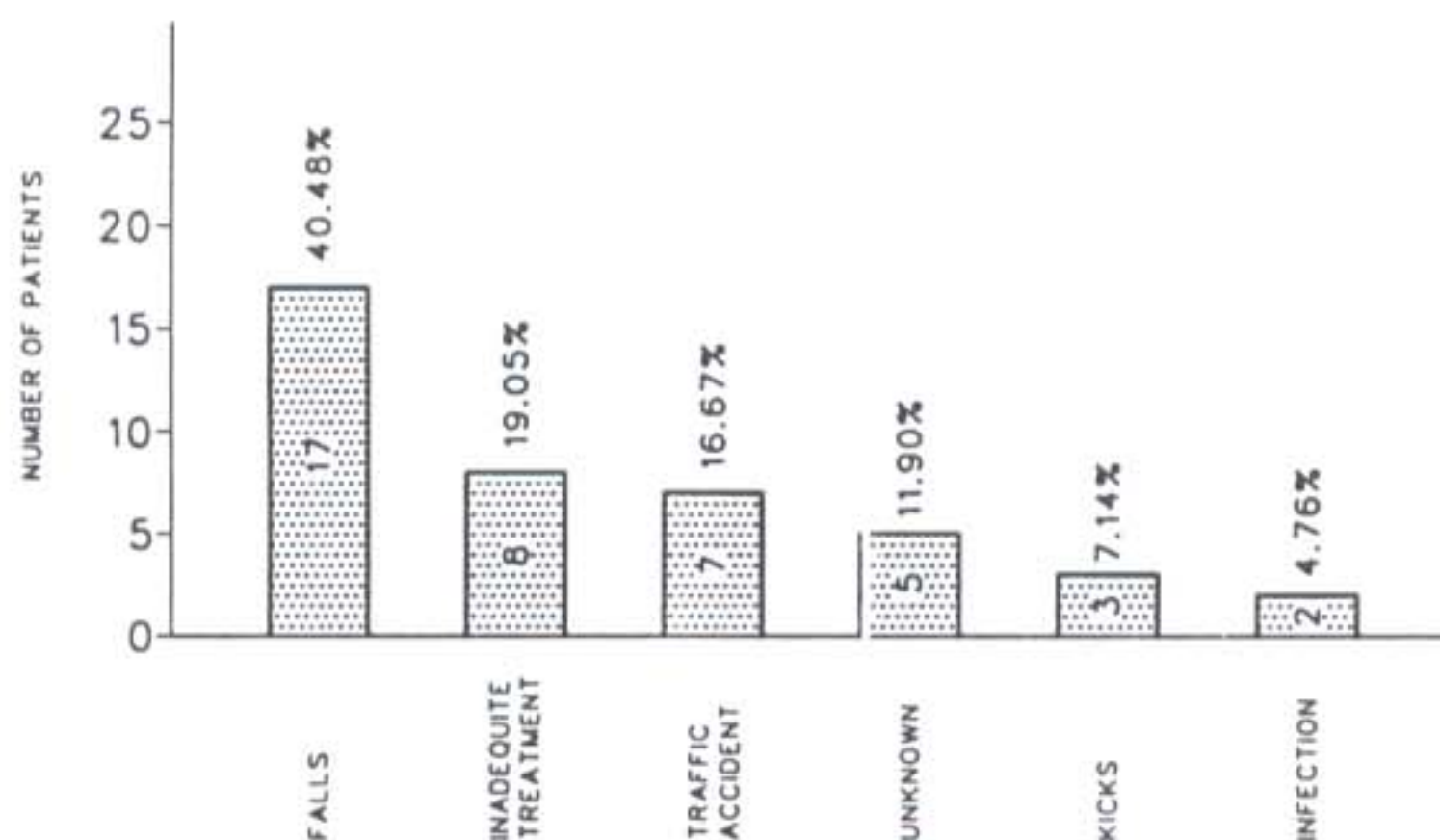


Fig. 2. Causes of the TMJ ankylosis.

The incision was deepened avoiding injury to the superficial temporal vessels and the facial nerve. The dissection proceeded in this plane to zygomatic arch and extended anteriorly and posteriorly to expose the limits of the ankylosis. The periosteum over the zygomatic arch and the ramus were incised and elevated. After exposure of the site of bony block, bone was removed by using a round burr until a thin cortical bone was left in the depth. In order not to injure the internal maxillary artery or pterygoid plexus of veins, two segments were gently split and fractured by using a chisel. The irregular edges of the segments were shaved by burr and disconnected completely the ramus from the upper bony block. Internal maxillary artery was inadvertently damaged in three of the patients who needed a second operation because of reoccurrence. In all of the cases bleeding was taken under control by packing.

It was interesting to observe that in all the unilateral cases, the side originally not affected by TMJ ankylosis was fully functional despite the fact that it had remained dormant for many years.

From the viewpoint of the techniques we used, patients fell into three groups (Fig. 3).

In most of the operations (45.24%), after creating a gap, a spherical acrylic spacer was placed between the two segments (Fig. 4). In order to place the spacer, two concave cavities were prepared on both articular surfaces using a big round burr (Fig. 5).

This technique was first described by Borçbakan [32]. The small spherical spacer was preferred in the cases where there was wide bony bridge across the ramus of the mandible. Fig. 6 reveals a huge bony block of osteoma. In this case, due to excessive bone formation, resection was made on the ascending part of the ramus just above the impacted third molar (Fig. 7), followed by the placement of the acrylic spacer. The second group of 18 patients were treated by gap arthroplasty through removing only a segment of bone and no

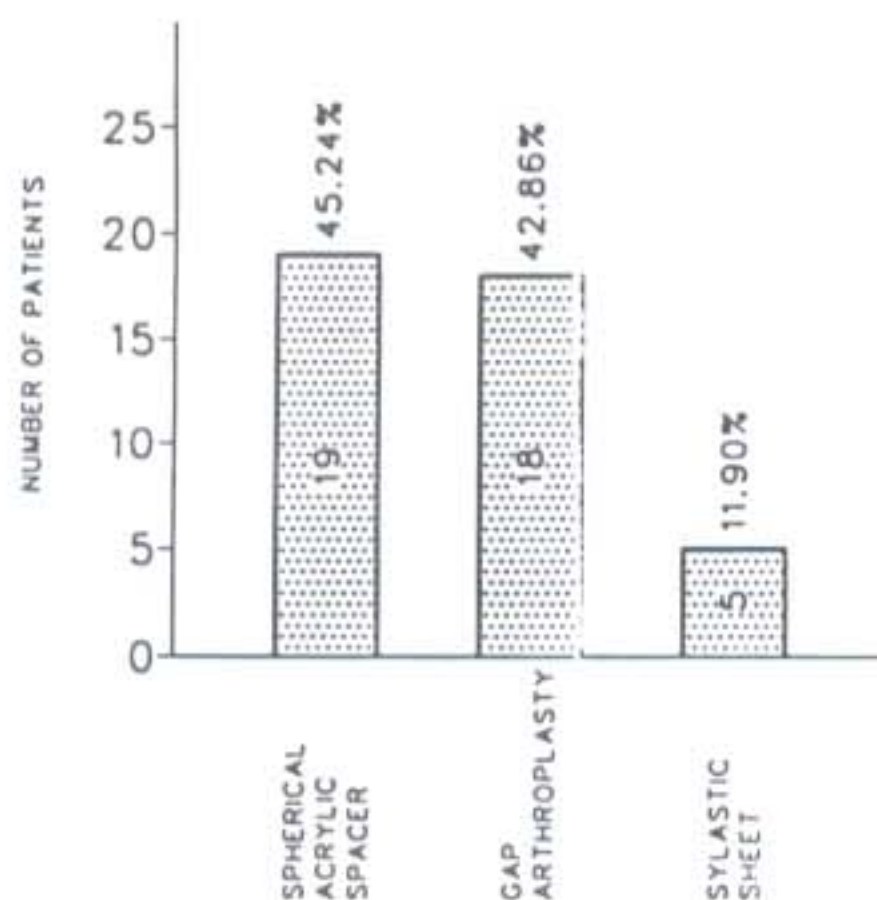


Fig. 3. Treatment used.

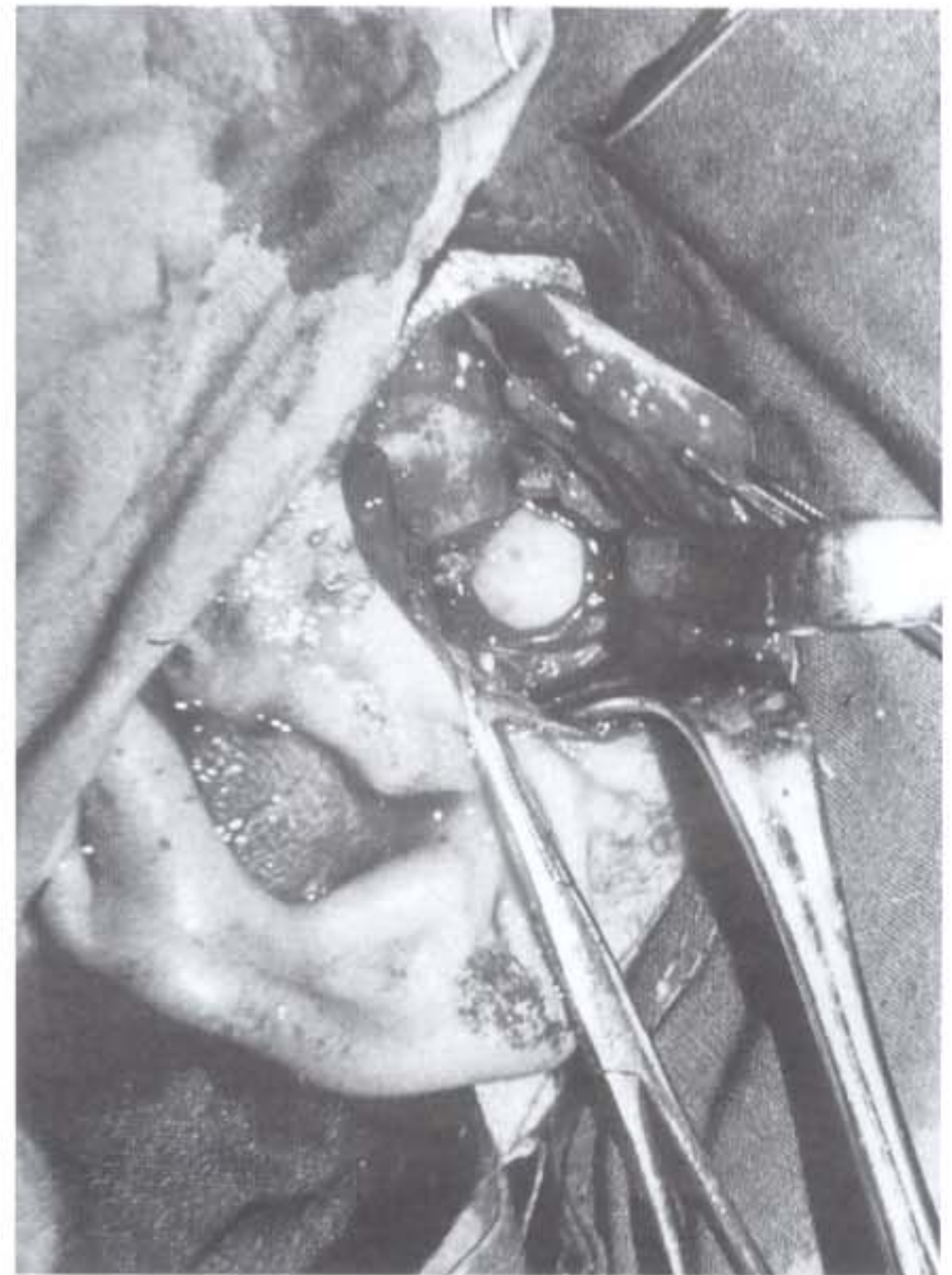


Fig. 4. Intraoperative view of reconstruction. Spherical acrylic spacer was placed between the two segments.

spacers were used. In the treatment of five patients, after disconnecting the segments, sylastic sheet was placed as interposition material and fixed by a screw.

After the operation, all the patients were encouraged to exercises intensively by opening and closing their mandible. Although physiotherapy was painful in the first week, most of the patients showed gradual progress during this time. Different type of gags were used to help and increase mouth opening. For this purpose, we designed different size of wooden gags (Fig. 8), interinsical acrylic gag increased mouth opening gradually by the help of a jack screw (Fig. 9).

4. Results

Gap arthroplasty without spacer and the sylastic sheet as an interposition material were preferred in the cases which did not have severe ankylosis. Removal of the wide segment and placement of the acrylic spacer was preferred in the ankylosis with a thick bony block. The round acrylic spacer distracted the two segments and allowed free posterior, anterior, medial and lateral movements. Moreover, it prevented reunion of the articular surfaces. Only three of the patients who had gap arthroplasty needed a second operation; these were the patients who rejected the early aggressive physiotherapy and regular postoperative controls.



Fig. 5. Diagram of the procedure.

Orthodontic and occlusal problems were corrected depending on the patients' desire. All the patients except for a few of them were from the rural areas and their economic and cultural levels were poor. Relevantly, the expectation of the patient and his/her family was only the opening of the jaw and the ability of mastication. Only a few of them needed orthodontic rehabilitation after surgery.

In the postoperative period, facial paresthesia and other complications concerning the parotid gland were not noted in any of the patients. However, deviation was present in eight of the patients who had gap arthroplasty without using the spacer and six of the patients had unilateral ankylosis. As part of our treatment during the early stages of physiotherapy patients were coerced to exercise their mandibles. Varying degrees of pain were reported by the patients during and after exercises. By taking analgesics and antiinflammatory medication, the pain was considerably reduced and patients were able to exercise within a week.

Our investigation of the patients after surgery revealed that those who had gap arthroplasty, their IO ranged from 30 to 40 mm. Those who were reluctant

to exercises could only open mandibles 20–30 mm by the week following operation. Although a slight relapse was seen in this group, the spacer did not let the IO go below 30 mm. However, mouth opening was not less than 25 mm in patients who had the acrylic spacer. None of the cases showed foreign body reaction.



Fig. 6. Radiograph of patient demonstrating a huge bony block in TMJ area.

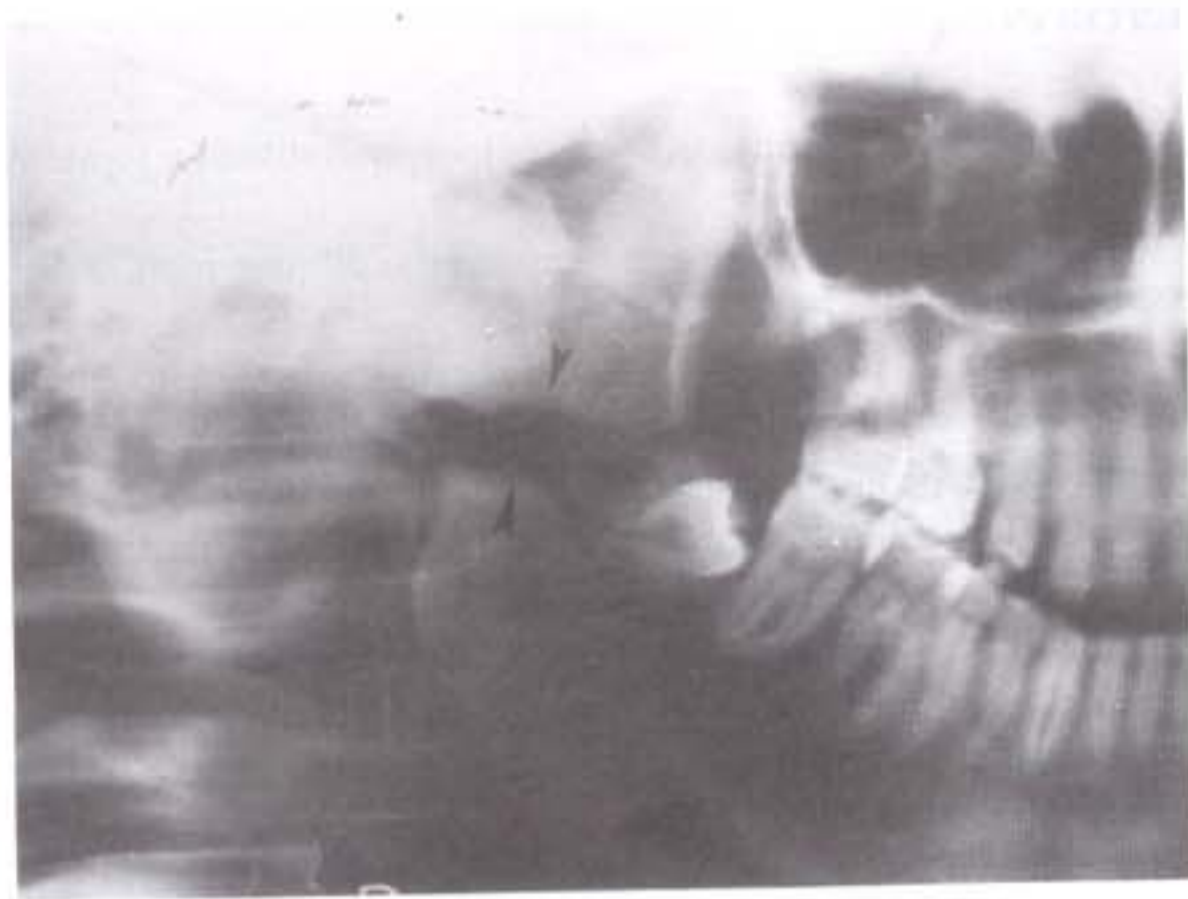

Fig. 7. Postoperative panoramic radiograph demonstrating the level of resection.




Fig. 8. Wooden mouth gag.

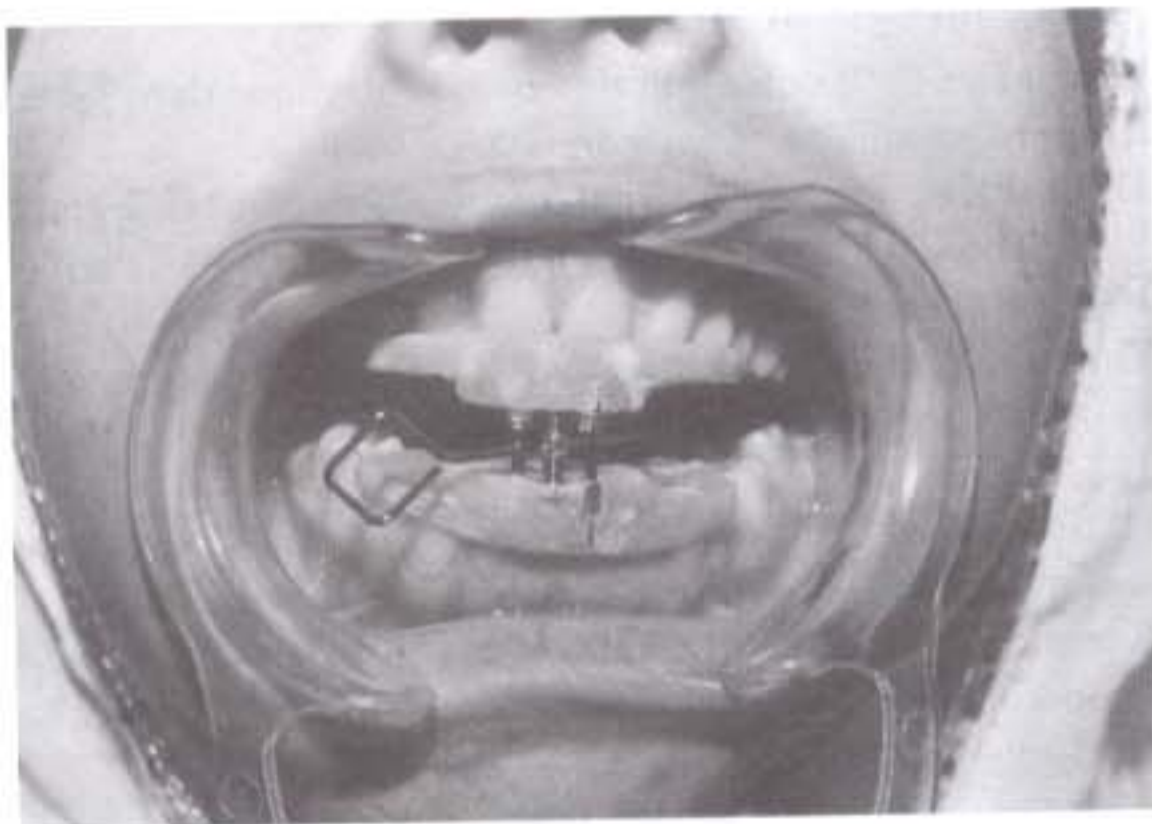

Fig. 9. Interinsical acrylic gag with jack screw.

5. Discussion

The treatment of the TMJ ankylosis should include surgery, even though surgery techniques may vary from one country to the next. To the best of our knowledge, the first condylectomy was performed by Humprey [33]. Verneuil [5] made the first interposition arthroplasty. During the last decades of 19th

century, Rizzoli [34] described horizontal resection of ramus in TMJ ankylosis. Risdon [35] used gold foil in the glenoid fossa to prevent reankylosis, then Eggers [36] described the placement of tantalum foil in arthroplasty. The following year, Walker (1958) [37] advocated the use of fascia and sylvastic in TMJ ankylosis. In the following years, Christensen [38] and Robinson [39] reported some modifications of metallic fossa implants. Borçbakan [16] reported the first largest series, consisting of 110 cases with surgical treatment of TMJ ankylosis using acrylic condyle. Kent et al. [40] reported successful results with the use of proplast coated metallic condylar prosthesis. A series of Kent prosthesis was followed for up to 10 years. Ninety percent of the cases were described successful in that they maintained the ramus height while maintaining or increasing interinsical opening and lateral mandibular excursion. To overcome the erosion into the glenoid fossa, total TMJ replacement including an artificial fossa was fostered by Kent et al. [40] and also by Sonnenburg and Sonnenburg [41]. However, in the following years, foreign body granuloma with painful inflammation was reported by some authors [42,43]. Reported cases of foreign body granulation tissue due to the reaction to silicone debris are few. Cope et al. [25] reported a detailed study on their experience with the Nicole–Calnan compressible silicone rubber prosthesis. In 1983, Rajgopal et al. [45] reported the cases treated by gap arthroplasty. The results were similar when comparing with the report of Topazian [10]. Our results were assumed similar to Rajgopal et al. [44] except for three cases. In 83.33% of cases who had gap arthroplasty, the results were satisfactory. In the technique of gap arthroplasty, the success of the operation correlated with the wideness (size) of the gap. Raveh et al. [45] presented their retrospective experience with 26 cases of full bony TMJ ankylosis using aggressive bone removal. According to Raveh [45], many surgeons are very concerned about damage to facial nerve and thus perform only a limited exposure and resection, leaving most of the ankylotic tissue medially along the glenoid fossa and skull base. Accordingly, the gap created is relatively thin and insufficient to enable optimal opening and free movements. Aggressive resection, early mobilization, insistent postoperative physiotherapy will produce satisfactory movement. This technique has some disadvantages as anterior open bite deformity due to removing a massive amount of bone from the ramus and the possibility of damage to internal maxillary artery. Among the advantages of this technique is shorter operating time and more importantly, its very low cost. This technique also enables us to overcome

the treatment of excessive TMJ ankylosis. Ankylosis with fusion of the coronoid process was treated by horizontal osteotomy in the ascending ramus.

Our patients were between 1 and 20 years old and the overall age distribution was similar to patients treated by Borçbakan [16]. Sawhney [3] and Borçbakan [16] studied on a population of 70 and 88 patients, respectively, and reported no foreign body reaction which is in compliance with our findings.

The type of the acrylic spacers we used were spherical. The spherical spacers enabled the patients for all jaw movements including lateral movements as well compared with the spacer applied by Sawhney [3] who reported limited movement.

In general, trauma is the most predominant etiologic factor of TMJ ankylosis. The severity of trauma affects the bony thickness of ankylosis and the type of necessary treatment. The number of our cases resulting from infection was less than those of Borçbakan's [16] in the same population. The widespread use of antibiotics at the earliest sign of infection, a common practice, may explain the less incidence infection. A total of 19.05% of the cases were due to inadequate treatment. These cases were treated by the specialists of other disciplines. The causes might be the false diagnosis, insufficient resection and postoperative physiotherapy. Five cases were noted in etiologic classification as unknown, had no history about the failure of their mandibular movements. These cases probably had resulted from falls or from birth trauma.

In unilateral ankylosis the other remarkable observation was that opposite joints remained healthy for many years. As it is well known, intermaxillary fixation restricts the movement of healthy condyles even for 4–6 weeks.

In recent papers, use of metallic TMJ condylar prosthesis [40] great toe joint [3] and costochondral grafts [46] are the subject of discussion in treatment of TMJ ankylosis. These techniques have some disadvantages such as difficulty in fixing the toe into the mandibular fragment, excessive growth of costochondral grafts and indication of metallic TMJ prosthesis for patients above 15 years.

The approach described in this study suggests the following principles necessary to overcome the TMJ ankylosis: (1) wide bone resection; (2) use of interpositional space if it is needed; (3) long-lasting early, aggressive postoperative physiotherapy.

As mentioned above, TMJ ankylosis is related with cultural and economic level of the patients. Early diagnosis of the TMJ can be deterrent to normal mandibular growth. The frequency of occurrence is rare in the population of young patients who undergo orthodontic treatment.

References

- [1] Kazanjian VH. Ankylosis of temporomandibular joint. *Surg Gynaecol Obstet* 1938;67:333–48.
- [2] Rowe NL. Ankylosis of the temporomandibular joint. *J R Coll Surg Edinburgh* 1982;26:67–79.
- [3] Sawhney CP. Bony ankylosis of the temporomandibular joint: follow-up of 70 patients treated with arthroplasty and acrylic-spacer interposition. *Plast Reconstr Surg* 1986;77:29–38.
- [4] Güven O. Temporomandibular eklem ankilozunda cerrahi tedavi. *Otorinolaring Stom Derg* 1987;1:24–7.
- [5] Verneuil A. De la création d'une fausse articulation par section ou résection partielle de l'os maxillaire inferieur comme moyen de remedier a l'ankylose vraie ou fausse de la machoire inferieur. *Arch Gen Med* 1860;15:174.
- [6] Stutville OH, Larfranchi RP. Surgical reconstruction of the temporomandibular joint. *Am J Surg* 1955;90:940–50.
- [7] Taher AAY. Treatment of TMJ ankylosis. *Plast Reconstr Surg* 1994;93:44.
- [8] Hinds EC, Pleasants JE. Reconstruction of the temporomandibular joint. *Am J Surg* 1955;90:931–9.
- [9] Kummoona R. Functional rehabilitisation of ankylosed temporomandibular joints. *Oral Surg* 1978;46:495–505.
- [10] Topazian RG. Comparison of the gap and interposition arthroplasty in treatment temporomandibular ankylosis. *J Oral Surg* 1966;24:405–9.
- [11] Murphy JB. Arthroplasty for intra-articular bony and fibrous ankylosis of the temporomandibular articulation. Report of nine cases. *J Am Med Assoc* 1914;62:1783–94.
- [12] Narang R, Dixon RA. Temporomandibular arthroplasty with fascia lata. *Oral Surg* 1975;39:45–50.
- [13] Popescu V, Vasiliu D. Treatment of temporomandibular ankylosis with particular reference to the interposition of full thickness skin autotransplant. *J Maxillofac Surg* 1977;5:3–14.
- [14] Siemssen SO. Temporomandibular arthroplasty by transfer of the sterno-clavicular joint on muscle pedicle. *Br J Plast Surg* 1982;35:225–38.
- [15] Cobey MC. Arthroplasties using compressed ivalon sponge. *Clin Orthop* 1967;54:139–44.
- [16] Borçbakan C. L'utilisation du condyle acrylique dans l'ankylose temporo-maxillaire. *Rew Stom* 1968;69:600–3.
- [17] Davis PKB, Jones SM. The complication of silastic implants. Experience with 137 consecutive cases. *Br J Plast Surg* 1971;24:405–11.
- [18] Taurus SP, Jordan JE, Keen RR. Temporomandibular joint ankylosis corrected with a gold prosthesis. *J Oral Surg* 1972;30:767–73.
- [19] Hatrtwell SW, Hall MD. Mandibular condylectomy with silicone rubber replacement. *Plast Reconstr Surg* 1974;53:440–4.
- [20] Khein CL, DesPrez JP, Converse CF. A new procedure for temporomandibular joint replacement. Case report. *Plast Reconstr Surg* 1974;53:221–6.
- [21] Alpert B. Silastic tubing for interpositional athroplasty. *J Oral Surg* 1978;36:153.
- [22] Posnick JC, Jacops JS, Magee WP. Prosthetic replacement of the condylar head for temporomandibular joint disease. *Plast Reconstr Surg* 1987;80:536–44.
- [23] Szabo G, Barabas J, Matral J, György J, Miklos L. Application of compact aluminium oxide ceramic implants in maxillofacial surgery. *J Oral Maxillofac Surg* 1990;48:354–61.
- [24] MacAfee KE, Quinn PD. Total temporomandibular joint reconstruction with delrin titanium implant. *J Craniofac Surg* 1992;3:160–9.
- [25] Cope MR, Moos KF, Hammersley N. The compressible silicone rubber prosthesis in temporomandibular joint disease. *Br J Oral Maxillofac Surg* 1993;31:376–84.

- [26] Bifano CA, Hubbard G, Ehler WJ. Total reconstruction of the temporomandibular joint with cryogenically preserved allograft mandibular condyle, meniscus, and fossa in the adult goat. *Oral Surg Oral Med Oral Pathol Oral Radiol Endod* 1995;80:267–72.
- [27] Norman J, Ede B. In: Norman J, Ede B, Bramley P, editors. *A Textbook and Color Atlas of the Temporomandibular Joint*, Ch. 9. London: Wolfe, 1990.
- [28] Martis C, Marti K. Temporomandibular joint ankylosis: the problem of restoration. *Hell Period Stomat Gnathopatho-prosopike Cheir* 1990;5:135–40.
- [29] Kalamchi S, Walker RV. Silastic implant as a part of temporomandibular joint arthroplasty. Evaluation of its efficiency. *Br Oral Maxillofac Surg* 1987;25:227–36.
- [30] Kirk Ws Jr., Farrar Jh. Early surgical correction of unilateral TMJ ankylosis and improvement in mandibular symmetry with use of an orthodontic functional appliance. A case report. *Cranio* 1993;11:308–11.
- [31] Guyot L, Choossegras C, Cheynet F, Gola R, Lachard J, Blanc JL. Clinique de stomatologie et chirurgie maxillo-faciale. *Rev Stomatol Chir Maxillofac* 1995;96:372–8.
- [32] Borçbakan C. Personal communication, 1990.
- [33] Humprey GW. Excision of the condyle of the lower jaw. *Assoc Med J* 1826;160:61–2.
- [34] Rizzoli F. Histoire d'une immobilité de la machoire inferiore traité par un nouveau procéd opératoire. *Bull Soc Med Chir* 1858;9:81.
- [35] Risdon FE. Ankylosis of the temporomandibular joint. *Bone Joint Surg* 1946;28:603–6.
- [36] Eggers GWN. Arthroplasty of temporomandibular joint in children with interposition of tantalum foil: A preliminary report. *Bone Joint Surg* 1946;28:603–6.
- [37] Walker RV. Arthroplasty of the ankylosed temporomandibular joint. *Am Surg* 1958;24:474–85.
- [38] Christensen RW. Mandibular joint arthrosis corrected by the insertion of cast vitallium glenoid fossa prosthesis: a new technique. *Oral Surg* 1958;17:712–22.
- [39] Robinson M. Temporomandibular ankylosis corrected by creating a false silastic sponge fossa. *J S CA Dental Assoc* 1968;36:14–6.
- [40] Kent JN, Misiek DJ, Akın RK, Hinds EJ, Hamsy CA. Temporomandibular joint condylar prosthesis: a ten year report. *J Oral Maxillofac Surg* 1983;41:245–51.
- [41] Sonnenburg I, Sonnenburg M. Total condylar prosthesis for alloplastic jaw articulation replacement. *J Maxillofac Surg* 1985;13:131–5.
- [42] Wagner DW, Mosby EL. Assesment of proplast-teflon disc replacements. *J Oral Maxillofac Surg* 1990;48:1140–4.
- [43] Fortenot MG, Kent JN. In vitro wear performance of proplast TMJ disc implants. *J Oral Maxillofac Surg* 1992;50:133–9.
- [44] Rajgopal A, Banerji PK, Batura V, Sural A. Temporomandibular ankylosis. A report of 15 cases. *J Maxillofac Surg* 1983;11:37–41.
- [45] Raveh J. Surgical treatment and long term results. *J Oral Maxillofac Surg* 48:666.
- [46] El-Sheikh MM, Medra AM. Management of unilateral temporomandibular ankylosis associated with facial asymmetry. *J Cranio-Maxillofac Surg* 1997;25:109–15.